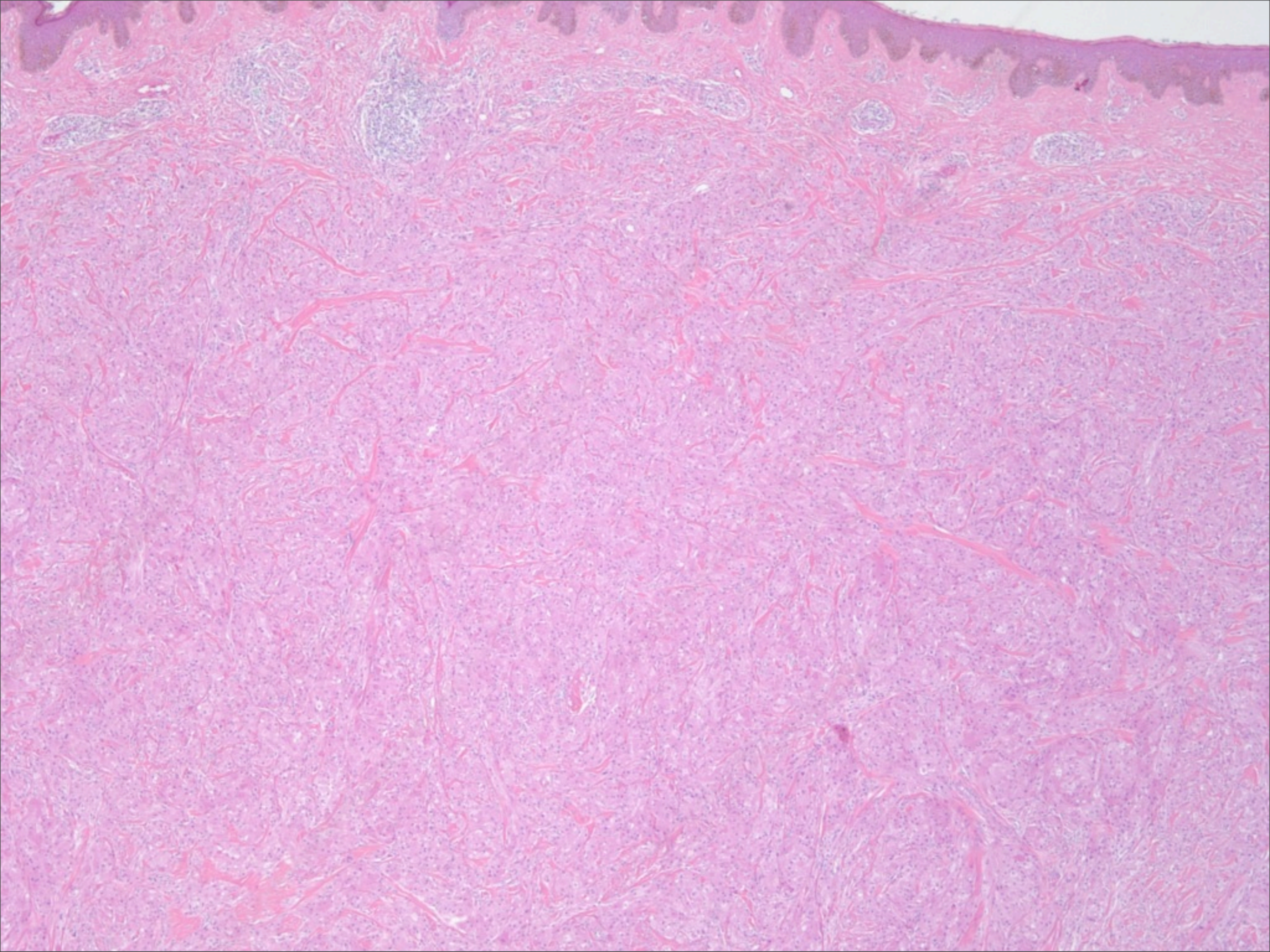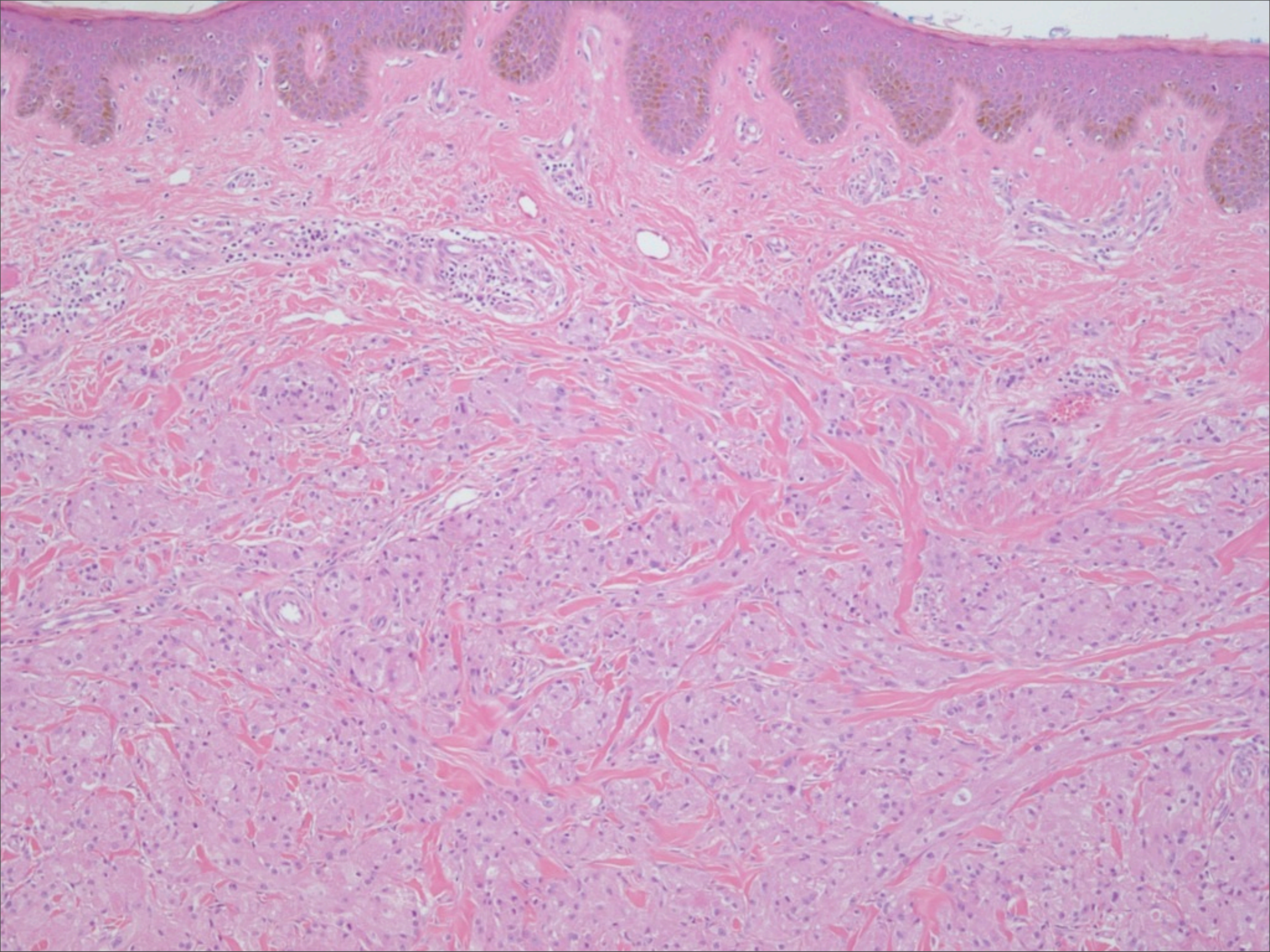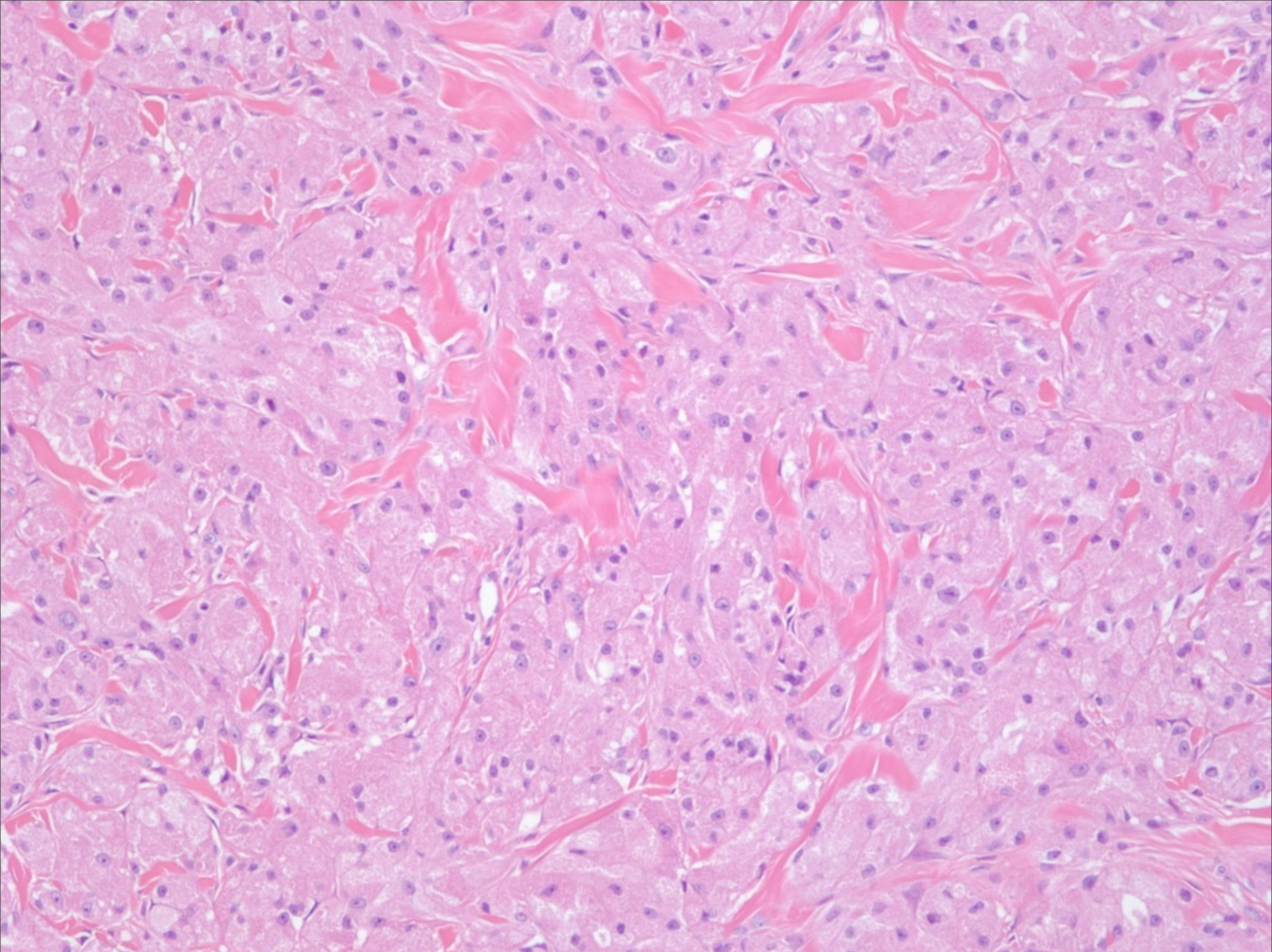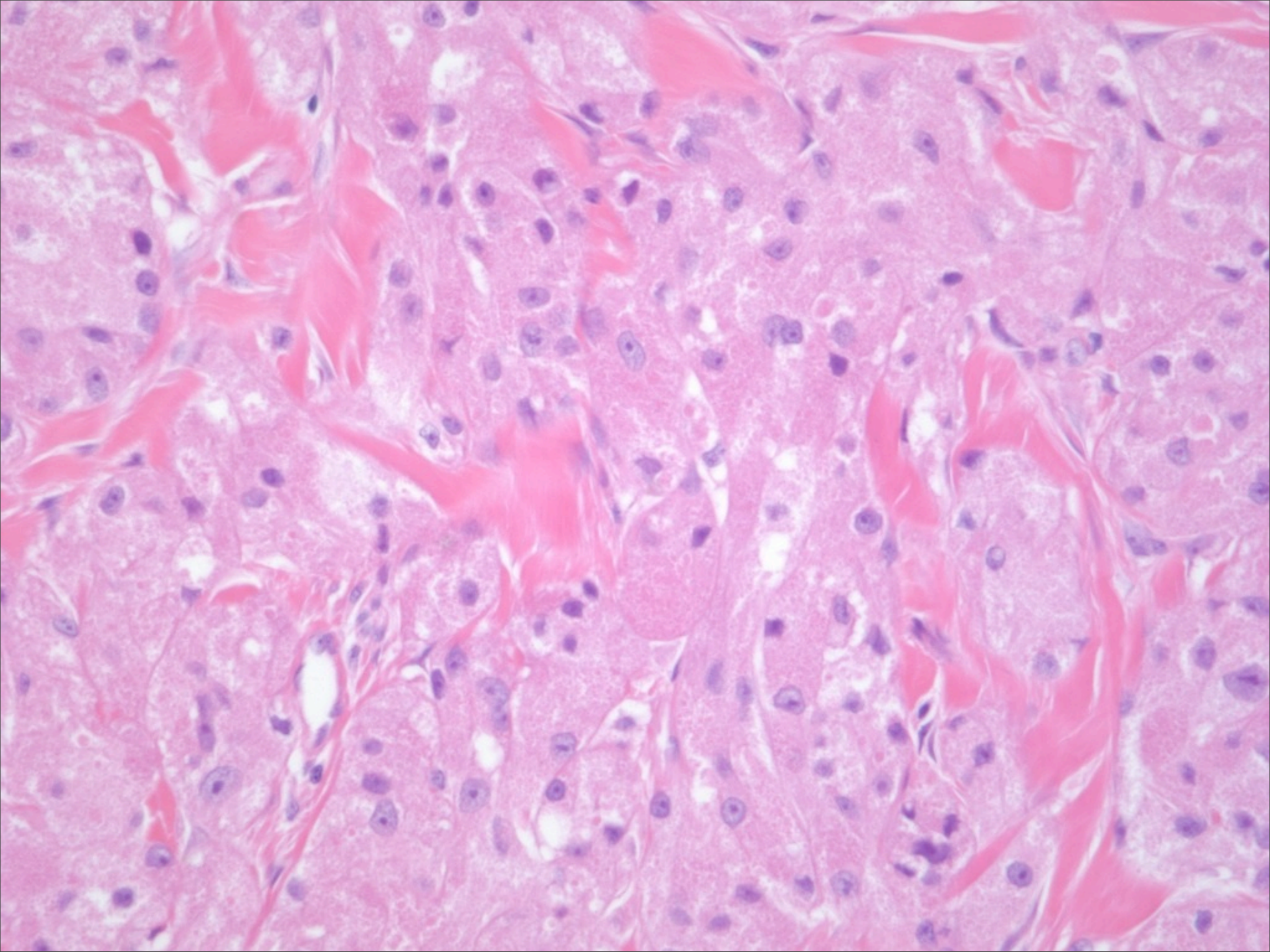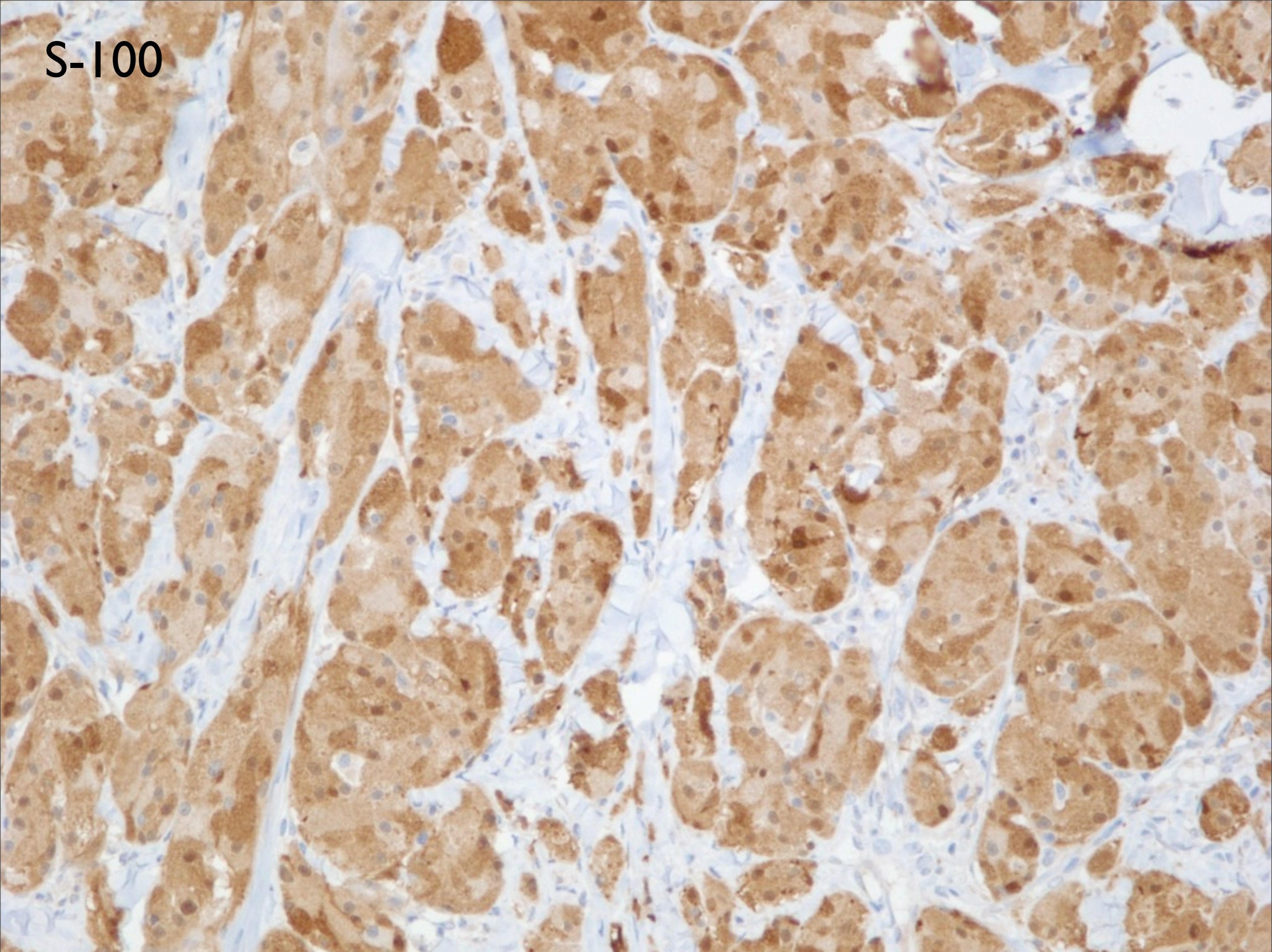
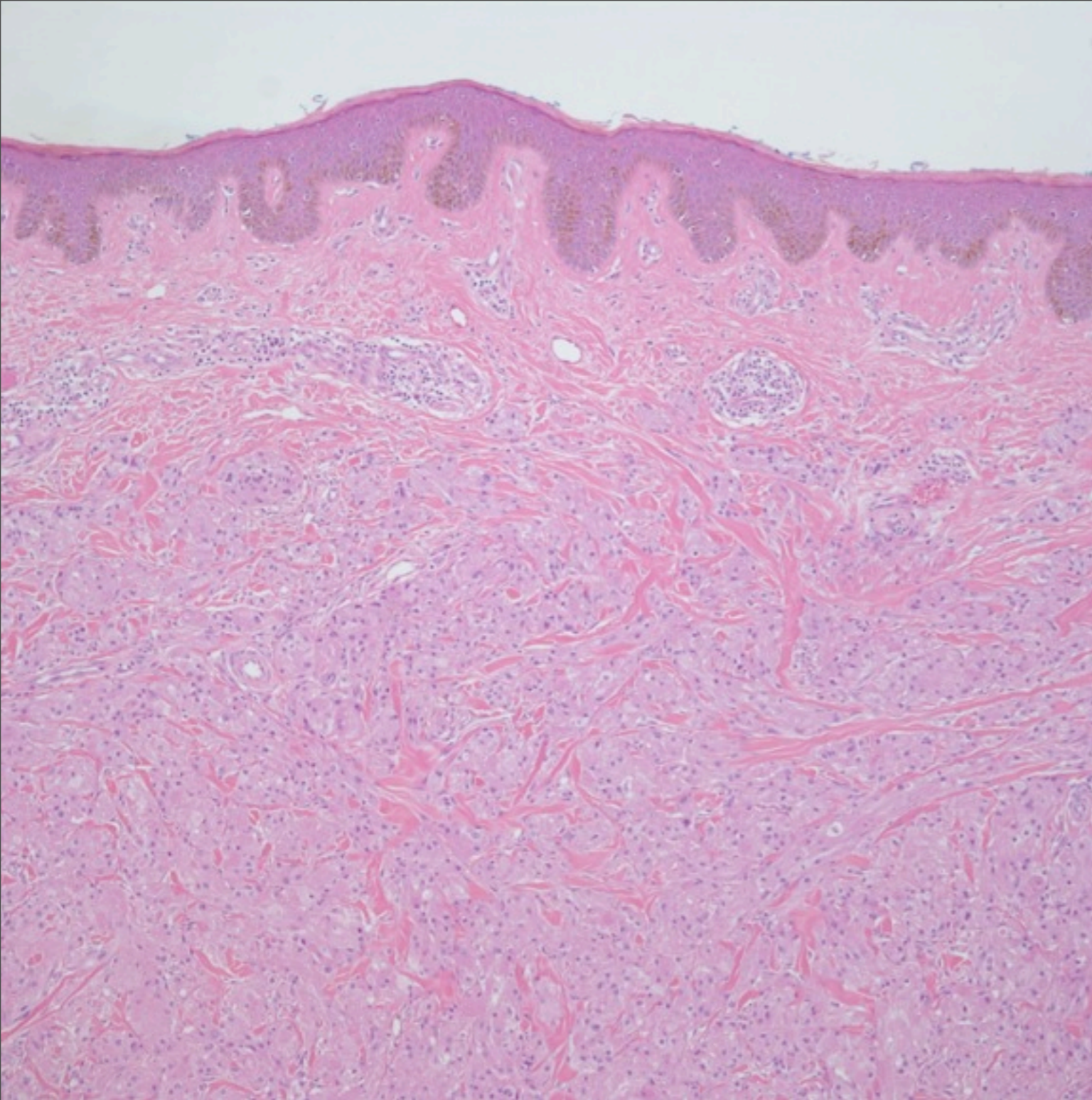


S-100



Granular Cell Tumor



Variable Epidermal
Hyperplasia

Diffuse infiltrate of
Granular Cells

Minimal Cytologic Atypia

Low Mitotic Rate

Confirm with immunohistochemistry-S100 positive